

The Cortical Representation of Speech

B. M. Mazoyer, N. Tzourio, V. Frak, and A. Syrota
CEA, Orsay, and CHU Bichat, Paris

N. Murayama, O. Levrier, and G. Salamon
CHU La Timone, Marseille

S. Dehaene, L. Cohen, and J. Mehler
INSERM, CNRS, and EHESS, Paris

Abstract

■ In this study, we compare regional cerebral blood flow (rCBF) while French monolingual subjects listen to continuous speech in an unknown language, to lists of French words, or to meaningful and distorted stories in French. Our results show that, in addition to regions devoted to single-word comprehension, processing of meaningful stories activates the left middle

temporal gyrus, the left and right temporal poles, and a superior prefrontal area in the left frontal lobe. Among these regions, only the temporal poles remain activated whenever sentences with acceptable syntax and prosody are presented. ■

INTRODUCTION

The emergence of language is one of the finest accomplishments of the human mind. This competence manifests itself by oral or written language in most adults. These language modalities are not at all equivalent. Indeed, while speech comes naturally and spontaneously to most children, reading requires explicit instruction for it to emerge. Therefore, the study of speech is likely to contribute more to our understanding of the biological foundations of language than the study of reading and writing (Lennenberg, 1967).

Psycholinguistic models have tried to explain how the acoustic wave is mapped onto phonemes, how the sequence of phonemes contacts the lexicon, and how words are concatenated into phrases to which a meaning can be attributed. One may also ask, not only how these cognitive processes are organized and structured, but also how they are implemented in the brain.

Positron emission tomography (PET) makes it possible to observe active cerebral areas while normal subjects process language (Alavi, Reivich, Greenberg, Hand, Rosenquist, Rintelman, Christman, Fowler, Goldman, MacGregor, & Wolf, 1981; Mazziotta, Phelps, Carson, & Kuhl, 1982; Mazziotta, Phelps, & Halgren, 1983; Kushner, Schwartz, Alavi, Dann, Rosen, Silver, & Reivich, 1987; Petersen, Fox, Posner, Mintun, & Raichle, 1988; Petersen, Fox, Snyder, & Raichle, 1990; Wise, Chollet, Hadar, Friston, Hoffner, & Frackowiak, 1991; Frith, Friston, Liddle,

& Frackowiak, 1991). So far, PET studies have mainly examined the cortical anatomy of single-word comprehension and production (Petersen et al., 1988, 1990; Wise et al., 1991; Frith et al., 1991). Both visual and auditory word presentations have been used. However, no PET studies on the comprehension of connected speech have come to our attention. Connected speech is a smooth and effortless mode of communication that humans generally use. However, it is this smooth and effortless aspect of speech that has made it so difficult to study. Brain imaging techniques can help to uncover the cortical areas that are involved in speech understanding and the interactions in which these regions get involved.

To perceive and understand speech, one must deal with the acoustical, phonological, lexical, prosodic, syntactic, and conceptual information conveyed by the signal. The auditory stimulus has first to be mapped into a phonological code. This code is invariant across speakers, speech rate, and accent. When a sequence of phonemes combines into an existing word, the mental lexicon is activated. For example, the word BED is recognized in the mental lexicon as a familiar item with a given meaning. This is not the case when one listens to a pseudoword, e.g., DEB. Eventually, syntactic processes specify the structure of the sentence, making it possible to interpret its meaning.

During language acquisition, these components become attuned to the properties of the target language. Thus, infants encode the acoustic signal into a phonetic

sequence. After a few months of experience, the code becomes dependent on the language the infant has been exposed to. A lexicon can then be acquired, allowing for the comprehension of single words and ultimately of connected speech.

The purpose of our study is to evaluate the existence, in the human brain, of specialized cerebral regions corresponding to these levels of linguistic analysis. Neuropsychology and experimental psycholinguistics have pursued similar aims with results that are accepted with varying degrees of confidence by most practitioners. By and large, most neuropsychologists accept that in most subjects the left hemisphere is more involved with speech than the right hemisphere. Aphasiology has established that lesions in and around Broca's area can yield aphemia and even more elaborate comprehension and production deficits. Likewise, lesions to the left posterior temporal lobe can produce sentence comprehension deficits in so-called Wernicke's aphasics. Some neuropsychologists (Ross, 1985) claim that difficulty understanding and controlling prosody may arise after right rather than after left hemisphere lesions.

In this study subjects listen to speech stimuli designed to evaluate the regions involved in the processing of the acoustic signal, of the phonological sequence, of lexical items, and of the prosodic structure as well as the syntactic and conceptual structures (Table 1).

In a first protocol, we investigated the areas that are involved when listening to continuous speech in one's maternal tongue. Subjects were asked to listen attentively to stories in French or in a language unknown to them, i.e., Tamil, a Dravidian language spoken in India and Sri Lanka. Tamil was chosen because it sounds subjectively unfamiliar to French speakers. We thought that the comparison of brain activation patterns across these two

conditions would uncover areas responsible for phonological, lexical, and syntactic processing as well as semantic integration. A second protocol was designed to select, among these areas, those responsible for continuous speech analysis in contrast to those that deal with single-word processes. Finally, a third protocol attempted to disrupt semantic integration while preserving syntax and prosody. Subjects listened to stories that were distorted either by replacing each content word with a pseudoword, or by replacing each content word with a semantically unrelated word of the same frequency, grammatical category, syllabic length, and imageability.

The 16 voluntary French young male subjects were first given an MRI study at the same axial brain levels as the PET slices, which were gathered subsequently. Each subject received 6 injections of oxygen-15-labeled water. Following each injection, a single 80-sec scan was acquired, with subjects listening to one of the prerecorded tapes, except for the silent rest control condition.

RESULTS

In the first protocol (see Table 2, Figs. 1 and 2), seven regions of interest were uncovered after the examination of a parcellation of the brain into 80 regions of interest having anatomical boundaries (Rademacher, Galaburda, Kennedy, Filipek, & Caviness, 1992): the left and right superior temporal gyri (LST, MST), the left and right temporal poles (LTP, RTP), the left middle temporal gyrus (LMT), the left inferior frontal gyrus (LIF), and a left superior prefrontal region corresponding to Brodmann's area 8 (LBA8). These and only these regions (and their contralateral counterparts) were used to present the results of the three protocols. No other region was observed as being activated in the last two protocols.

Table 1. Experimental Design^a

	Story in Tamil	List of French Words	Distorted Stories		Story in French
			Sentences with Pseudowords	Semantically Anomalous Sentences	
Putative processing systems					
Acoustical	✓	✓	✓	✓	✓
Phonological	—	✓	✓	✓	✓
Lexical	—	✓	—	✓	✓
Prosodic	—	—	✓	✓	✓
Syntactic	—	—	✓	✓	✓
Conceptual	—	—	—	—	✓

^aFive categories of speech stimuli are used to neutralize specific components within a hierarchy of putative speech processing systems. Acoustical processing is performed in all conditions. Language-specific phonological analysis is possible for our French monolingual subjects only with French stimuli, but not with Tamil stimuli. Lexical processing is possible with lists of words, semantically anomalous sentences, and stories in French. Prosodic and syntactic analysis is available only with distorted and meaningful stories. Finally, the conceptual level is attained only when listening to meaningful stories in French.

Table 2. Summary of Analyses of Variance^a

	Protocol 1			Protocol 2			Protocol 3		
	Task	Repl	Inter	Task	Repl	Inter	Task	Repl	Inter
Right superior temporal	0.002	0.82	0.24	<10 ⁻⁴	0.36	0.13	0.0007	0.63	0.73
Left superior temporal	<10 ⁻⁴	0.44	0.59	<10 ⁻⁴	0.004	0.34	0.013	0.71	0.12
Right middle temporal	0.87	0.28	0.68	0.15	0.016	0.04	0.22	0.47	0.94
Left middle temporal	0.004	0.49	0.38	0.01	0.053	0.11	0.38	0.28	0.028
Right temporal pole	0.008	0.23	0.37	0.004	0.081	0.35	0.012	0.58	0.07
Left temporal pole	0.0002	0.055	0.12	0.002	0.006	0.12	0.017	0.90	0.30
Right inferior frontal	0.38	0.63	0.94	0.25	0.36	0.60	0.097	0.25	0.13
Left inferior frontal	0.024	0.93	0.58	0.041	0.069	0.45	0.091	0.19	0.010
Right superior prefrontal	0.46	0.78	0.16	0.57	0.85	0.08	0.77	0.87	0.04
Left superior prefrontal	0.027	0.53	0.17	0.033	0.28	0.59	0.58	0.43	0.50

^aResults of the analyses of variance conducted in the three protocols. Within each anatomical ROI, *NrCBF* was estimated in the PET images as the ratio (in percent) of the radioactivity concentration in the region to that of the whole brain. Regional data were analyzed as a 3 (tasks) by 2 (replicates) factorial design with repeated measurements on the subject factor ($N = 5$ or 6).

Both left and right superior temporal gyri were activated in all conditions of auditory stimulation (Tables 3, 4, and 5, Fig. 1). These were the only regions active while listening to the stories in Tamil (Tables 2, 3). In the first protocol (Table 3), listening to the stories in French activated three additional temporal regions (Figs. 1, 2, and 3): the left and right temporal poles, and the left middle temporal gyrus. The only significant extratemporal activations were found within the left frontal lobe, namely in the inferior frontal gyrus and in a superior frontal area (see Tables 2, 3, and 6). Even in regions that were bilaterally activated, i.e., the superior temporal gyri and the temporal poles, activation was always significantly higher in the left hemisphere than in the right (Table 7, Fig. 3). These results were replicated in the second protocol using two new stories in French.

The word list condition activated only a subset of the regions active during story listening (Table 4): the left and right superior temporal gyri common to all conditions, and the inferior frontal gyrus on the left (Fig. 1). By subtraction, one may infer that the activations in the left middle temporal gyrus, in the temporal poles, and in the superior frontal area on the left side reflect processing beyond the single-word level. Among these, only the temporal poles were significantly activated when listening to distorted stories (Table 5, Fig. 3). In both types of distorted stories, there was also a significant asymmetry in the middle temporal gyrus, the left being more active than the right (Table 7, Fig. 3). Only when listening to sentences with pseudowords was there an additional activation of the right inferior frontal gyrus.

DISCUSSION

How do these results improve our understanding of the cerebral bases of speech comprehension? We shall first

consider in turn the successive stages of analysis of the speech signal (acoustical, phonological, lexical, prosodic/syntactic, and conceptual), and their putative localizations based on our results. We shall then discuss more broadly how our results fit with a serial-stage framework of language processing, and emphasize an alternative view of the cooperation between brain areas involved in language comprehension.

Acoustical Analysis

The acoustical level of analysis can be mapped to bilateral activations of the superior temporal gyrus, a region that includes primary and secondary auditory areas. The superior temporal gyri have been reported in previous PET studies with auditory stimuli (Alavi et al., 1981; Mazziotta et al., 1982, 1983; Kushner et al., 1987; Petersen et al., 1988, 1990; Wise et al., 1991; Frith et al., 1991; Zatorre, Evans, Meyer, & Gjedde, 1992), and were the only regions to be activated by continuous speech regardless of whether it was understandable to the subject (French) or not (Tamil). However, the stories in French, contrary to those in Tamil, yielded an asymmetrical activation of these regions favoring the left hemisphere (Table 7). This suggests that this anatomically defined region of interest might include several brain areas with differing functional roles other than general-purpose acoustical analysis. One such area, localized to the left hemisphere, might be specialized for the mother language (see below).

Phonological Analysis

Speech, as opposed to other sounds, is composed of phonemes that may differ from one language to the next.

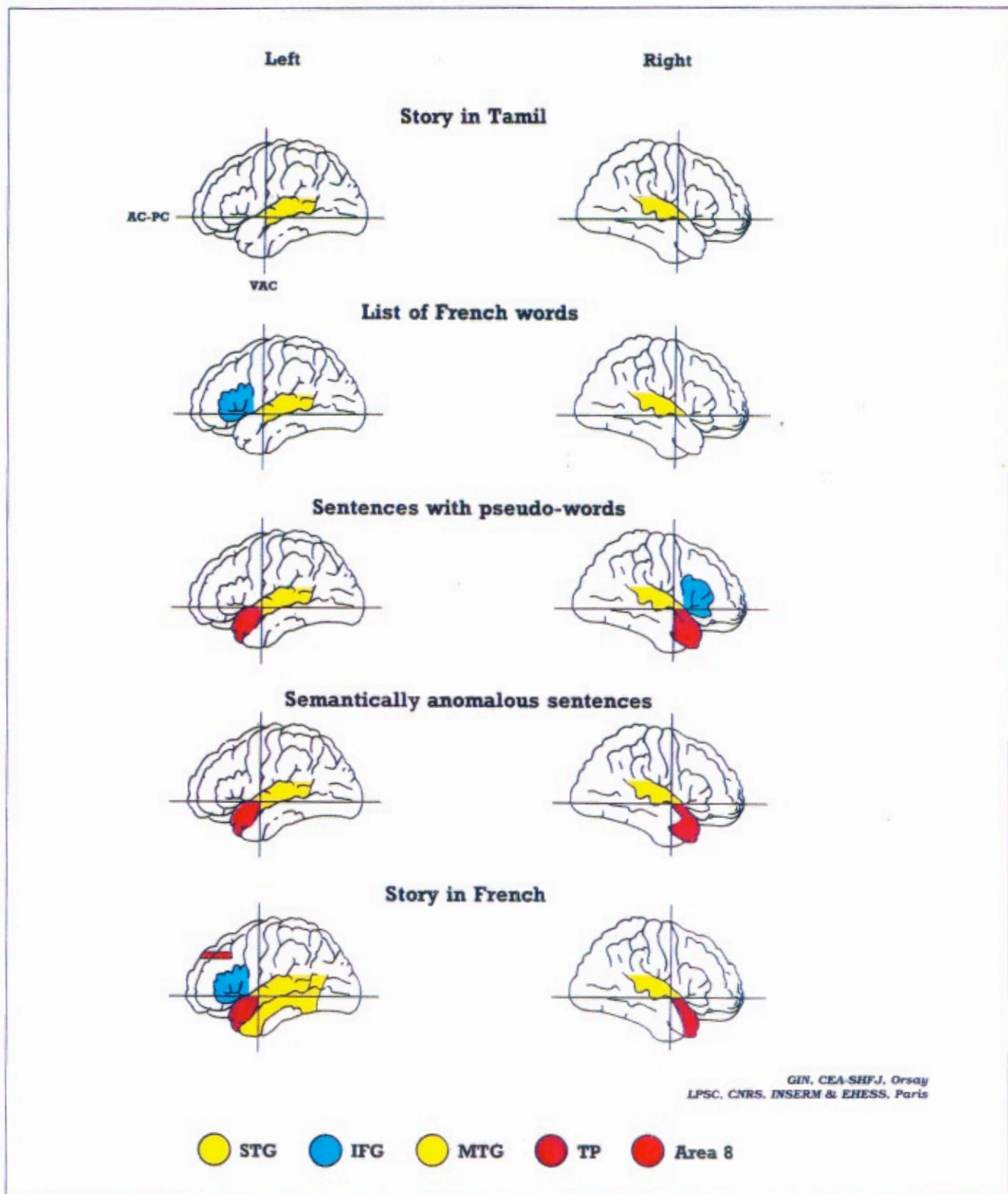


Figure 1. Active brain regions in the five experimental conditions: listening to a story in Tamil ($N = 5$), to a list of French words ($N = 5$), to sentences with pseudowords ($N = 6$), to semantically anomalous sentences ($N = 6$), and to a story in French ($N = 10$). Observed average regional activations were mapped on a reconstruction of the external brain surface of subject 10 based on high-resolution magnetic resonance images. The anterior commissure vertical plane (VAC) and the bicommissural plane (AC-PC) were used to limit the projection of the temporal pole region (TP). The inferior frontal gyrus region (IFG) includes the pars opercularis, triangularis, and orbitaris of the third frontal gyrus. A superior prefrontal area corresponding to Brodmann's area 8 (Area 8) was defined on individual MRI using a stereotactic atlas. STG, superior temporal gyrus region; MTG, middle temporal gyrus region.

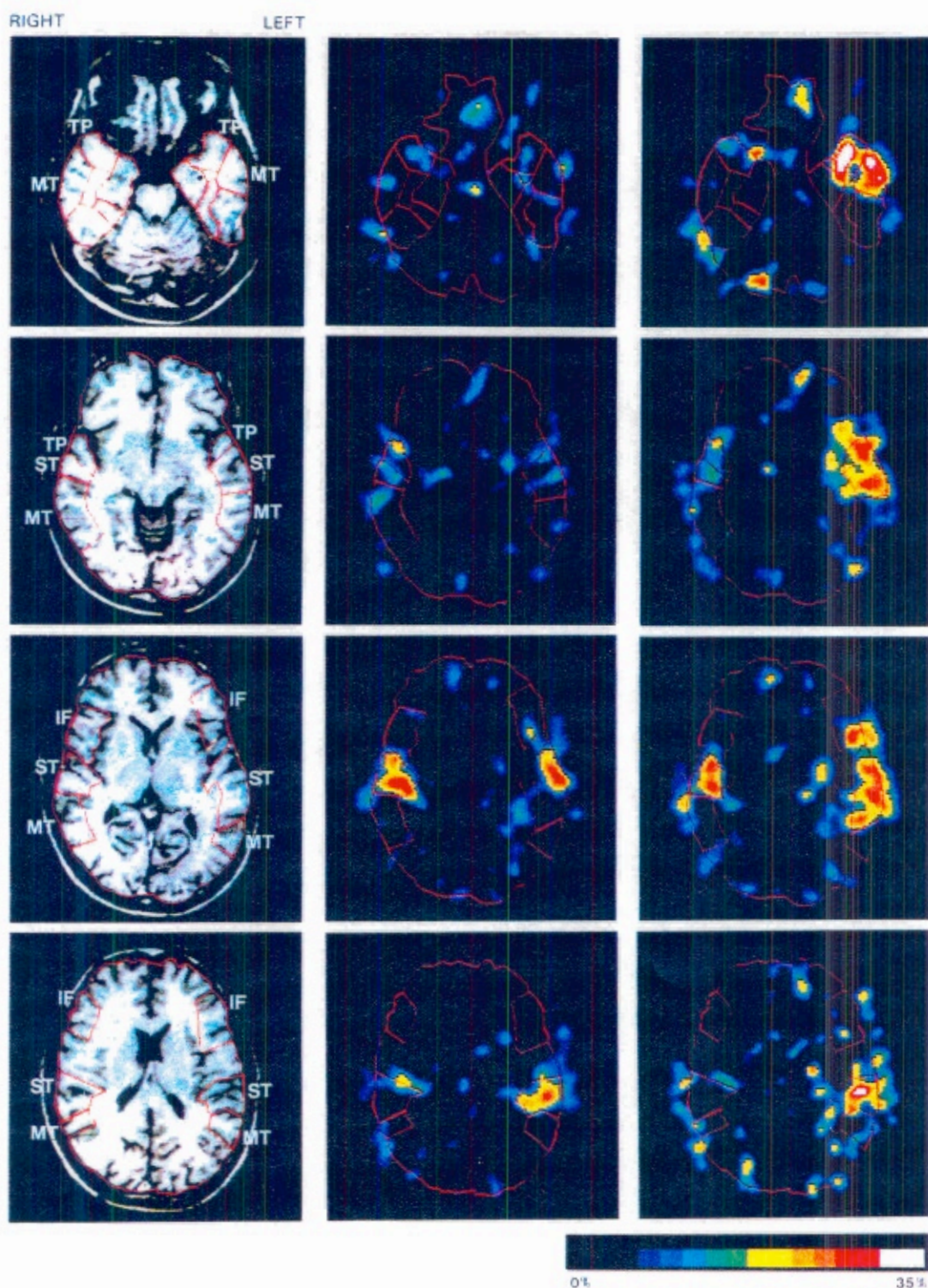


Figure 2. Example of individual normalized cerebral blood flow (NCBF) positron emission tomography (PET) activation images obtained at four different brain levels in the same subject (protocol 1, subject 3) while listening to a story in an unknown language (center column images) or to a story in his mother language (right column images). Activation images were obtained by subtracting NCBF PET images acquired while subject listened to the stories to that obtained during a silent control condition. Anatomical limits of major gyri that were located using the subject brain MRI images (left column) are superimposed on activation images. IF, inferior frontal gyrus; MT, middle temporal gyrus; ST, superior temporal gyrus; TP, temporal pole.

Table 3. Activations during Protocol 1^a

	<i>Tamil versus Rest</i>			<i>Story in French versus Rest</i>		
	<i>Mean</i>	<i>SD</i>	<i>p Value</i>	<i>Mean</i>	<i>SD</i>	<i>p Value</i>
Right superior temporal	6.45	2.58	<10 ⁻⁴	6.86	3.52	0.0002
Left superior temporal	8.06	2.01	<10 ⁻⁴	10.25	3.54	<10 ⁻⁴
Right middle temporal	-0.15	1.38	0.73	0.77	2.00	0.79
Left middle temporal	0.39	3.02	0.62	5.03	3.97	0.003
Right temporal pole	2.40	4.28	0.11	8.05	4.77	0.0005
Left temporal pole	1.92	4.15	0.17	13.7	5.31	<10 ⁻⁴
Right inferior frontal	1.24	2.64	0.17	0.82	2.38	0.30
Left inferior frontal	0.33	2.17	0.64	2.07	3.19	0.07
Right superior prefrontal	0.74	4.85	0.16	-1.38	4.87	0.39
Left superior prefrontal	1.40	4.03	0.30	2.37	4.09	0.10

^aAverage percentage variations (in percent, as compared to the silent resting condition) of normalized cerebral blood flow (NrcBF) in selected regions of interest during protocol 1. *p* values are for Student's paired *t* test with *N* = 10.

Table 4. Activations during Protocol 2^a

	<i>Word List versus Rest</i>			<i>Story in French versus Rest</i>		
	<i>Mean</i>	<i>SD</i>	<i>p Value</i>	<i>Mean</i>	<i>SD</i>	<i>p Value</i>
Right superior temporal	6.17	2.63	<10 ⁻⁴	4.79	2.57	0.0002
Left superior temporal	8.12	2.58	<10 ⁻⁴	8.61	2.96	<10 ⁻⁴
Right middle temporal	-0.92	2.25	0.22	-1.35	2.71	0.15
Left middle temporal	1.58	2.21	0.053	4.05	3.05	0.002
Right temporal pole	0.22	4.29	0.87	5.49	4.24	0.002
Left temporal pole	0.84	4.03	0.52	7.72	5.12	0.001
Right inferior frontal	0.86	2.39	0.28	-0.98	3.41	0.38
Left inferior frontal	3.30	3.24	0.010	1.66	3.67	0.18
Right superior prefrontal	-0.66	5.11	0.72	1.41	4.51	0.40
Left superior prefrontal	0.86	2.41	0.34	4.55	3.93	0.13

^aAverage percentage variations (in percent, as compared to the silent resting condition) of normalized cerebral blood flow (NrcBF) in selected regions of interest during protocol 2. *p* values are for Student's paired *t* test with *N* = 10.

A brain area specialized for phonological analysis should therefore be active whenever the subject is processing words or sentences in his mother language, but not when hearing speech samples from a radically different language. Only one region of interest followed this predicted pattern (Table 7, Fig. 3). In the middle temporal gyrus, there was always a significant asymmetry in favor of the left when listening to French stimuli, but not when listening to Tamil stimuli. This suggests a role for the left middle temporal gyrus in language-specific phonological analysis, even though the activation of this region by itself did not always reach significance when compared to its resting value. This hypothesis is corroborated by another study (Zatorre et al., 1992) that found the left middle temporal gyrus to be active when subjects listen to monosyllabic words or pseudowords that followed the phonological rules of their mother language.

Lexical Analysis

Another level of structure in the speech signal is the word level. In our study, the left inferior frontal region was activated during the presentation of lists of words, pointing to its involvement in lexical functions. Indeed, other studies have also found left inferior frontal activations in language tasks such as silent reading of words (Petersen et al., 1990) or the silent generation of verbs associated with nouns (Wise et al., 1991). This region encompasses the critical area for Broca's aphasia. Neuropsychology has established that while lesions restricted to the frontal operculum may yield pure anarthria (Schiff, Alexander, Naeser, & Galaburda, 1983), larger lesions lead to both production and comprehension deficits. The present results confirm that this region is concerned with word comprehension and not just with production.

Table 5. Activations during Protocol 3^a

	<i>Pseudoword Sentences versus Rest</i>			<i>Semantically Anomalous Sentences versus Rest</i>		
	<i>Mean</i>	<i>SD</i>	<i>p Value</i>	<i>Mean</i>	<i>SD</i>	<i>p Value</i>
Right superior temporal	5.65	3.85	0.0004	4.27	2.86	0.0003
Left superior temporal	5.56	5.33	0.004	5.57	4.95	0.002
Right middle temporal	-0.65	1.92	0.26	-1.11	1.79	0.055
Left middle temporal	0.97	2.57	0.22	0.88	2.12	0.17
Right temporal pole	3.30	3.51	0.007	3.44	3.23	0.003
Left temporal pole	3.42	3.71	0.009	4.50	3.75	0.001
Right inferior frontal	2.30	3.03	0.023	1.10	3.27	0.26
Left inferior frontal	1.18	3.79	0.30	0.34	2.96	0.69
Right superior prefrontal	-0.31	2.85	0.71	-0.34	2.93	0.69
Left superior prefrontal	-0.27	3.42	0.78	-0.94	2.83	0.27

^aAverage percentage variations (in percent, as compared to the silent resting condition) of normalized cerebral blood flow (NrcBF) in selected regions of interest during protocol 3. *p* values are for Student's paired *t* test with *N* = 12.

In spite of its activation by single words, the left inferior frontal region ceased to be differentially activated while the subjects listened to semantically anomalous sentences that contained very similar words. This result may seem paradoxical, especially since it is widely accepted that lexical access is automatic (Stroop, 1935; Marslen-Wilson, 1987). However, task demands may modulate the depth of lexical processing and the amount of attention allocated to the lexical level (Cutler, Mehler, Norris, & Segui, 1987), and there is evidence that the PET methodology is especially sensitive to attention allocation (Corbetta, Miezen, Dobmeyer, Schulman, & Petersen, 1990). It should be noted that this region is not always active during the passive presentation of words (Wise et al., 1991). We speculate that listening to meaningless sentences discourages subjects from attending to word meaning to such an extent that the residual activation becomes undetectable.

Conceptual, Syntactic, and Prosodic Analysis of Continuous Speech

Turning now to story comprehension processes, we observed a significantly asymmetrical activation of the superior temporal gyri only when listening to meaningful stories in French. The stories in French were also the only stimuli to activate the left middle temporal gyrus significantly as compared to rest. Even though there was already a comparable asymmetry in this region with all French stimuli, meaningful stories activated it to a significantly higher degree. This suggests that in addition to their role in acoustical and phonological analysis, these regions of interest might also encompass a functional brain area involved in sentence-level processing. Indeed, lesions in the left posterior temporal lobe can yield

sentence comprehension deficits in patients referred to as Wernicke's aphasics. There is some consensus that the critical site for Wernicke's aphasia is the posterior part of the left superior temporal gyrus. Moreover, some lesion studies have emphasized the role of the middle temporal gyrus (Naeser, Helm-Estabrooks, Haas, Auerbach, & Srinivasan, 1987; Damasio, 1990) while others have favored the left inferior parietal lobule (Damasio, 1990). Lesions of the inferior parietal lobule have long been known to induce language impairments such as conduction aphasia. However, the critical anatomical structure responsible for the deficit may not be the gray matter itself, but rather the subcortical fiber bundles running below it (arcuate fasciculus (Geschwind, 1965)). In our study, as in previous PET investigations (Petersen et al., 1988, 1990; Wise et al., 1991; Frith et al., 1991), no activation was found in the left supramarginal and angular gyri. We speculate that the arcuate fasciculus was functional during story listening, but failed to be uncovered by PET scanning, a technique that is mostly sensitive to synaptic activity.

What could be the functional role of the left superior and middle temporal areas found active during listening to meaningful stories? Listening to meaningless distorted stories did not give rise to a similar strong activity in these regions. This would seem to suggest that they are highlighted only when the meaning of a sentence is computed. Indeed, the inferior part of the left temporal lobe has been implicated in the generation of mental images from verbal stimuli (Mazziotta et al., 1983; Goldenberg, Podreka, Steiner, & Willmes, 1987; Farah, Hammond, Levine, & Calvanio, 1988), a process that might be triggered during the comprehension of concrete stories. An alternative hypothesis, however, is that these regions may be truly devoted to sentence-level processing, including syntactic parsing, but these routines are

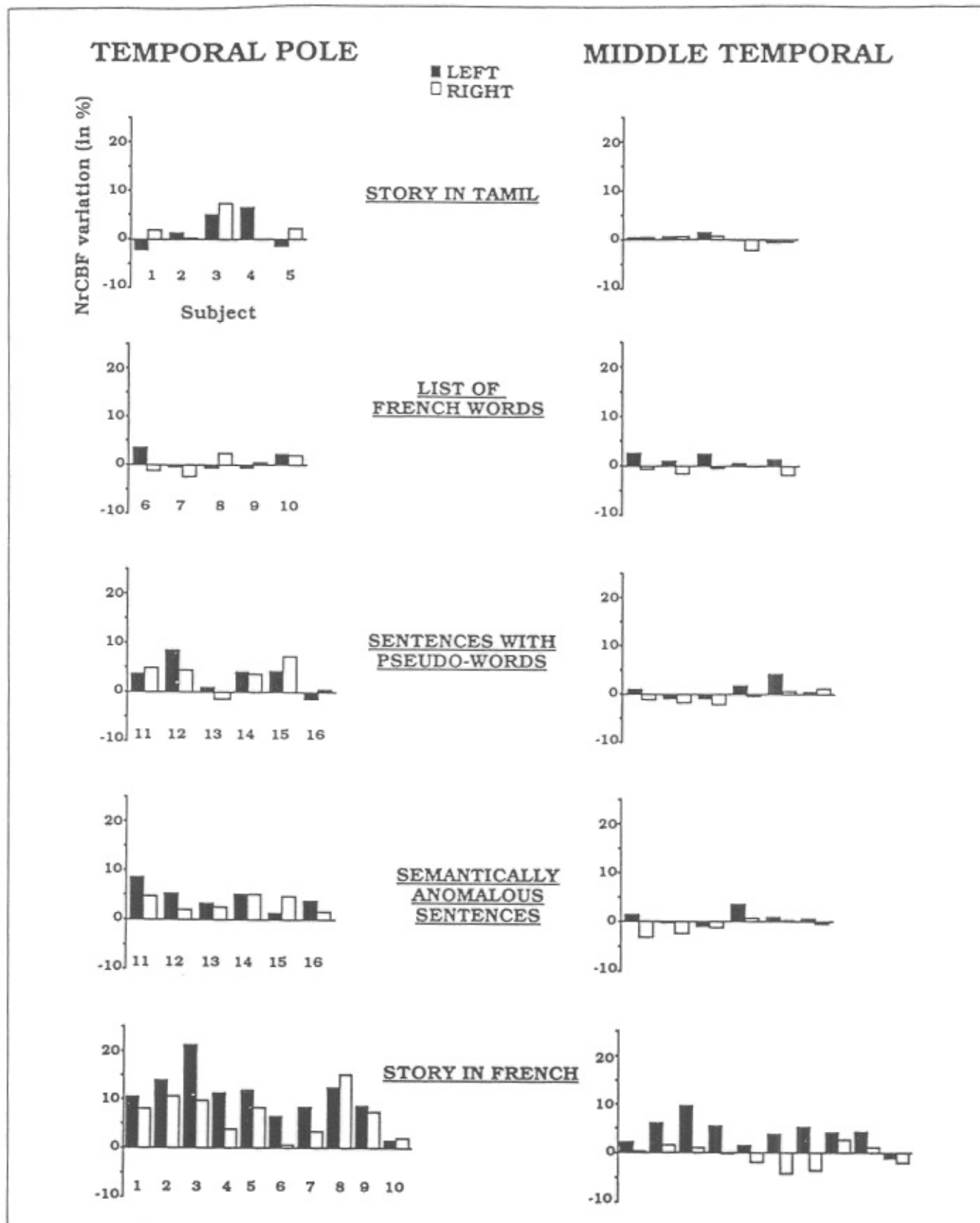


Figure 3. Individual percentage variation in normalized cerebral blood flow (NrCBF) in selected regions of interest when listening to a story in Tamil (subjects 1 to 5), to a list of French words (subjects 5 to 10), to sentences with pseudowords (subjects 11 to 16), to semantically anomalous sentences (subjects 11 to 16), or to a story in French (subjects 1 to 10). Open bars, right side region; closed bars, left side region.

Table 6. Activations during Story in French (All Subjects Pooled)^a

	<i>Story in French versus Rest</i>		
	<i>Mean</i>	<i>SD</i>	<i>p Value</i>
Right superior temporal	5.82	3.18	<10 ⁻⁴
Left superior temporal	9.43	3.28	<10 ⁻⁴
Right middle temporal	-0.59	2.44	0.29
Left middle temporal	4.54	3.48	<10 ⁻⁴
Right temporal pole	6.77	4.59	<10 ⁻⁴
Left temporal pole	10.71	5.93	<10 ⁻⁴
Right inferior frontal	-0.08	3.01	0.90
Left inferior frontal	1.87	3.35	0.022
Right superior prefrontal	-0.14	4.79	0.90
Left superior prefrontal	3.34	4.06	0.002

^aAverage percentage variations (in percent, as compared to the silent resting condition) of normalized cerebral blood flow (NrcBF) in selected regions of interest while subjects listened to stories in their mother language (protocols 1 and 2 were pooled). *p* values are for Student's paired *t* test with *N* = 20.

Table 7. Activation Asymmetries (Left-Right)^a

	<i>Stories in Tamil</i>	<i>Word List</i>	<i>Pseudoword Sentences</i>	<i>Semantically Anomalous Sentences</i>	<i>Stories in French</i>
Superior temporal	1.61 (2.98, 0.12)	1.95 (3.40, 0.10)	-0.09 (4.38, 0.94)	1.29 (3.90, 0.27)	3.60 (4.16, 0.001)
Middle temporal	0.54 (3.03, 0.58)	2.50 (1.61, 0.0008)	1.62 (2.40, 0.039)	1.99 (1.88, 0.003)	5.13 (3.76, <10 ⁻⁴)
Temporal pole	-0.48 (5.49, 0.78)	0.62 (3.88, 0.62)	0.12 (3.60, 0.91)	1.06 (3.11, 0.26)	3.94 (4.19, 0.0005)
Inferior front	-0.91 (2.79, 0.32)	2.44 (2.34, 0.0092)	-1.12 (3.20, 0.22)	-0.76 (3.41, 0.45)	1.95 (4.04, 0.044)
Superior prefrontal	0.66 (3.72, 0.58)	1.62 (4.84, 0.40)	0.03 (3.82, 0.97)	-0.60 (3.09, 0.51)	3.48 (4.83, 0.007)

^aLeft minus right average percentage variations (in percent, as compared to the silent resting condition) of normalized cerebral blood flow (NrcBF) in selected regions of interest during the various auditory stimuli used in the three protocols. *p* values are for Student's paired *t* test with *N* = 10 (columns 1 and 2), *N* = 12 (columns 3 and 4), or *N* = 20 (column 5).

largely disrupted when listening to stories that have been distorted either by introducing pseudowords or by eliminating the semantic relations between words.

In our paradigm, regions that are dedicated to syntactic parsing or prosodic analysis should have been systematically activated by continuous speech in French, regardless of its meaning (Table 1). The only regions that correspond to this definition are the left and right temporal poles. These areas were initially thought to be active during high anxiety (Reiman, Fusselman, Fox, & Raichle, 1989a) or panic attack (Reiman, Raichle, Robins, Mintun, Fusselman, Fox, Price, & Hackman, 1989b), but the results were in fact contaminated by the contraction of facial muscles during anxiety (Drevets, Videen, MacLeod, Haller, & Raichle, 1992). Anxiety and the ensuing

muscular contractions constitute equally unlikely explanations for our findings because heart rate, which was monitored only during the third protocol, did not vary during listening to distorted stories as compared to rest. Moreover, we also failed to observe blood flow modifications in the temporal muscle areas. Neuropsychology, however, has demonstrated that the anterior temporal region of the dominant hemisphere plays a central role in verbal learning and memory. Patients with damage to the left anterior temporal region typically show an impoverished recall of stories (Milner, 1958) despite intact sentence comprehension and working memory capacity (Frisk & Milner, 1990). Our data show an increasing activation of the left temporal pole as the stimuli engage more levels of linguistic processing. Whereas listening

to the melody of an unknown language, Tamil, activated both temporal poles moderately and symmetrically, listening to meaningful stories more than doubled this activation level and led to a significant asymmetry in favor of the left. While the left temporal pole may be related to memory for the linguistic content of the stimuli, the additional activation of the right temporal pole may reflect the encoding and storage of the pragmatic, prosodic, and other discursive aspects of the stories (Zatorre et al., 1992; Etcoff, 1990).

CONCLUSIONS

Our results are in many ways compatible with the standard teachings of neuropsychology. First, they demonstrate a clear superiority of the left hemisphere for speech processing, which was more pronounced as the stimuli increased in linguistic complexity. When subjects listened to a meaningful story in their mother language, all active brain areas showed a highly significant asymmetry in favor of the left hemisphere. Second, brain areas corresponding to the classical language centers were identified in our protocols. In that respect, the present study offered several advantages over the lesion method, by allowing for a precise anatomical definition of these regions separately for each subject, and by permitting, at least in some cases, to ascribe functions for each region (e.g., lexical processing for the left inferior frontal gyrus, and phonological processing for the left middle temporal gyrus). Moreover, our study also uncovered new brain areas related to speech processing. Indeed, one striking result of our study was the bilateral activation of the temporal poles whenever continuous speech was presented. Whether this activation reflects verbal and non-verbal memory processes, or an overlooked specialization of these regions for syntactic and prosodic processing, will be the focus of further experiments.

Finally, what view of the neural architecture of speech processing do our results imply? We hoped to identify the cortical correlates of specific subsystems of speech processing by a stepwise increase in the complexity of the linguistic content of the stimuli presented to subjects (Table 1). This approach was only partly successful. While the acoustical, phonological, and lexical components lent themselves to such an analysis in terms of serial stages, the distinction between syntactic, prosodic, and conceptual processes remained more elusive. According to a serial view of language processing, the semantically anomalous sentences should have permitted analysis up to and including the lexical and syntactic level. The pattern of activation in this condition should therefore have been close to that observed with meaningful stories, except for the absence of a conceptual component. The results, however, indicated that the large left-hemispheric network of areas active with meaningful stories reduced

to a sparse and weakly lateralized set when syntactically correct but meaningless sentences were presented. We believe that the speech processing system of the human brain is not organized, at the neural level, in a hierarchy of areas that successively and automatically come into play whenever they receive an adequately structured stimulus. Rather, speech processing seems to imply the coordination of a network of areas, each of which may be specialized in one aspect of speech processing, but requires coherent support from the others in order to reach a high level of activation.

METHODS

Subjects

Sixteen right-handed French healthy male medical students participated in this study. Mean subject age was 23.6 years (SD = 2.3 years). The study was approved by the Atomic Energy Commission Ethic Committee and all subjects gave written informed consent.

Task Design

Our first protocol investigated the brain areas for continuous speech in the mother tongue. Five right-handed French subjects were asked to listen attentively to stories in French or in a language unknown to them, i.e., Tamil, a Dravidian language spoken in India and Sri Lanka. Tamil was chosen because it sounds subjectively unfamiliar to French speakers. All stories were read by a female bilingual speaker with comparable pitch, intonation, and volume. The second protocol was designed to select, among these areas, those responsible for continuous speech analysis as opposed to single-word processing. Five other right-handed French subjects listened to stories in French or to lists of French words. The words of the lists were matched to the content words of the stories for grammatical category, frequency, syllabic length, and imageability. Function words and morphological inflexions were omitted. Finally, in the third protocol, six other right-handed French subjects listened to stories that were distorted either by replacing each content word with a pseudoword, or by replacing each content word with a semantically unrelated word of the same frequency, grammatical category, syllabic length, and imageability. The pseudowords respected the phonological rules of French, and morphological affixes were added whenever required to maintain sentence coherence. Both sentences with pseudowords and semantically anomalous sentences were read with adequate prosody. In each protocol, the instructions were as follows: sub-

jects were informed of the kind of protocol they were part of. They were explicitly told what kind of spoken stimuli they would listen to 30 sec prior to exposure and were instructed to passively but attentively listen to the speech stimuli.

Scanning Procedure

Using PET and oxygen-15-labeled water, normalized regional cerebral blood flow (NrcBF) was measured six times in each subject by replicating twice a series of three conditions: control, listening to a story in Tamil, listening to a story in French (protocol 1, subjects 1 to 5); control, listening to a list of French words, listening to a story in French (protocol 2, subjects 6 to 10); and control, listening to sentences with pseudowords, listening to semantically anomalous sentences (protocol 3, subjects 11 to 16). In all three protocols, the control condition consisted in resting silently with eyes closed with no particular consign except to relax. All auditory stimuli were presented binaurally over earphones, starting 45 sec before water injection, different speech stimuli being used for each replication.

For each condition, seven contiguous brain slices were simultaneously acquired on a time-of-flight PET system (Mazoyer, Trebossen, Schoukroun, Verrey, Syrota, Vacher, Lemasson, Monnet, Bouvier, & Lecomte, 1990). Following intravenous bolus injection of oxygen-15-labeled water (Herscovitch, Markham, & Raichle, 1983) a single 80-sec scan was reconstructed (including correction for head attenuation) starting at the arrival of the radioactivity in the brain, the scan duration being chosen to improve the signal-to-noise ratio in the difference images (Kanno, Iida, & Miura, 1991). Between-scan interval was 15 min. A series of 3-mm-thick T1-weighted high-resolution magnetic resonance images (MRI), at the same axial brain levels as the PET slices, were obtained in each subject.

Data Analysis

Our data analysis method has been detailed elsewhere (Petit, Orssaud, Tzourio, Salamon, Mazoyer, & Berthoz, 1993). It is aimed at detecting increases of cerebral blood flow in cerebral structures with anatomical boundaries. It is based on a parcellation of the brain similar to that recently proposed by others (Rademacher et al., 1992). In a first step, a detailed analysis of each subject brain anatomy was performed by means of a dedicated software (Voxtool, General Electric, Buc, France). MRI slices were used to reconstruct a three-dimensional brain volume that was further segmented and allowed the display of the external and internal surfaces of both hemi-

spheres. The major gyri could then be identified and their limits automatically marked onto the MRI axial slices. Using these anatomical landmarks, cortical regions of interest (ROI) with anatomical boundaries, corresponding to the intersection of the gyri with the MRI axial slices, were delineated on each subject's MRI images (see Fig. 2). Subcortical regions were directly delineated on MRI images. This method does not require complex operations of normalization to a fixed brain atlas, and takes into account interindividual anatomical differences (Galaburda, Rosen, & Sherman, 1990; Steinmetz & Seitz, 1991) as well as hemispheric anatomical asymmetries (Geschwind & Levitsky, 1968; Habib, Renucci, Vanier, Corbaz, & Salamon, 1984; Steinmetz, Volkman, Jäncke, & Freund, 1991). It also makes the ROI boundaries independent of the CBF PET images and provides regional activation values for each individual (Fig. 3). To compute regional normalized regional cerebral blood flow values (NrcBF), the seven PET slices acquired on each trial were then aligned with the subject high-resolution magnetic resonance images (MRI) by visually aligning three sets of isodensity contours automatically drawn on corresponding attenuation, blood flow, and MRI slices. Within each anatomical ROI, NrcBF was estimated as the ratio (in percent) of the radioactivity concentration in the region to that of the whole brain as measured in the PET images.

Statistical Analysis

The first protocol served for hypothesis generation by assuming that the larger number of activated ROIs would be observed while subjects listened to stories in their mother language and that other tasks would activate only a subset of these. Through this first step, a subset of seven regions of interest was selected that were further analyzed in the subsequent protocols. This strategy was selected to reduce the overall type I error. NrcBF within each anatomical region was compared across the three experimental conditions in each protocol, and between homologous regions in the left and right hemispheres. Regional data were analyzed as a 3 (tasks) by 2 (replicates) factorial design with repeated measurements on the subject factor ($N = 5$ or 6). Whenever the ANOVA global F test was found significant in a region at the 0.05 level (two-tailed), pairs of NrcBF values during task and control were compared with Student's paired t tests.

Acknowledgments

We thank Pr. J. Cambier for helpful discussions, and Laurence Raynaud, Monique Crouzel, and the Orsay radiochemistry staff for technical assistance. Funding for this work was provided by the Ministère de la Recherche et de la Technologie (Action Sciences de la Cognition) and by the Human Frontier Science Program.

Reprint requests should be sent to Dr. Jacques Mehler and/or Dr. Bernard Mazoyer, Service Hospitalier Frédéric Joliot, CEA-DRIPP, Place du Generale le Clerc, 91406 Orsay, Cedex, France.

REFERENCES

- Alavi, A., Reivich, M., Greenberg, J., Hand, P., Rosenquist, A., Rintelman, W., Christman, D., Fowler, J., Goldman, A., MacGregor, R., & Wolf, A. (1981). Mapping of Functional Activity in brain With 18F-Fluoro-Deoxyglucose. *Seminars in Nuclear Medicine*, *11*, 24–31.
- Corbetta, M., Miezin, F., Dobmeyer, S., Schulman, G. L., & Petersen, S. E. (1990). Attentional modulation of neural processing of shape, color, and velocity in humans. *Science*, *248*, 1556–1559.
- Cutler, A., Mehler, J., Norris, D., & Segui, J. (1987). Phoneme identification and the lexicon. *Journal of Cognitive Psychology*, *19*, 141–177.
- Damasio, H. (1990). Neuroimaging Contributions to the Understanding of Aphasia. In F. Boller & J. Grafman (Eds.), *Handbook of neuropsychology*. Amsterdam: Elsevier.
- Drevets, W. C., Videen, T. O., MacLeod, A. K., Haller, J. W., & Raichle, M. E. (1992). PET images of blood flow changes during anxiety: Correction. *Science*, *256*, 1696.
- Etcoff, N. J. (1990). Asymmetries in recognition of emotions. In F. Boller & J. Grafman (Eds.), *Handbook of neuropsychology*. Amsterdam: Elsevier.
- Farah, M. J., Hammond, K. M., Levine, D. N., & Calvanio, R. (1988). Visual and spatial mental imagery: Dissociable systems of representation. *Cognitive Psychology*, *20*, 439–462.
- Frisk, V., & Milner, B. (1990). The relationship of working memory to the immediate recall of stories following unilateral temporal or frontal lobectomy. *Neuropsychologia*, *28*, 121–135.
- Frith, C. D., Friston, K. J., Liddle, P. F., & Frackowiak, R. S. J. (1991). A PET study of word finding. *Neuropsychologia*, *29*, 1137–1148.
- Galaburda, A. M., Rosen, G. D., & Sherman, G. F. (1990). Individual variability in cortical organization: Its relationship to brain laterality and implications to function. *Neuropsychologia*, *28*, 529–546.
- Geschwind, N. (1965). Disconnexion syndromes in animals and man. *Brain*, *88*, 237–294–585–644.
- Geschwind, N., & Levitsky, W. (1968). Human brain: Left-right asymmetries in temporal speech region. *Science*, *161*, 186–187.
- Goldenberg, G., Podreka, I., Steiner, M., & Willmes, K. (1987). Patterns of regional cerebral blood flow related to memorizing of high and low imagery words—An emission computer tomography study. *Neuropsychologia*, *25*, 473–485.
- Habib, M., Renucci, R. L., Vanier, M., Corbaz, J. M., & Salamon, G. (1984). CT assessment of right-left asymmetries in the human cerebral cortex. *Journal of Computer Assisted Tomography*, *8*, 922–927.
- Herscovitch, P., Markham, J., & Raichle, M. E. (1983). Brain blood flow measured with intravenous H²¹⁵O. I. Theory and error analysis. *Journal of Nuclear Medicine*, *24*, 782–789.
- Kanno, I., Iida, H., & Miura, S. (1991). Optimal scan time of oxygen-15-labeled water injection method for measurement of cerebral blood flow. *Journal of Nuclear Medicine*, *32*, 1931–1934.
- Kushner, M. J., Schwartz, R., Alavi, A., Dann, R., Rosen, M., Silver, F., & Reivich, M. (1987). Cerebral glucose consumption following verbal auditory stimulation. *Brain Research*, *409*, 79–87.
- Lenneberg, E. H. (1967). *The biological foundations of language*. New York: Wiley.
- Marslen-Wilson, W. D. (1987). Functional parallelism in spoken word-recognition. *Cognition*, *71*, 71–102.
- Mazoyer, B. M., Trebossen, R., Schoukroun, C., Verrey, B., Syrota, A., Vacher, J., Lemasson, P., Monnet, O., Bouvier, A., & Lecomte, J. L. (1990). Physical characteristics of TTV03, a new high spatial resolution time-of-flight positron tomograph. *IEEE Transactions on Nuclear Science*, *37*, 778–782.
- Mazziotta, J. C., Phelps, M. E., Carson, R. E., & Kuhl, D. E. (1982). Tomographic mapping of human cerebral metabolism: Auditory stimulation. *Neurology*, *32*, 921–937.
- Mazziotta, J. C., Phelps, M. E., & Halgren, E. (1983). Local cerebral glucose metabolic response to audiovisual stimulation and deprivation: Studies in human subjects with positron CT. *Human Neurobiology*, *2*, 11–23.
- Milner, B. (1958). Psychological defects produced by temporal lobe excision. *Research Publication Association for Research in Neurology and Mental Diseases*, *36*, 244–257.
- Naeser, M. A., Helm-Estabrooks, N., Haas, G., Auerbach, S., & Srinivasan, M. (1987). Relationship between lesion extent in "Wernicke's area" on the computed tomographic scan and predicting recovery of comprehension in Wernicke's aphasia. *Archives of Neurology*, *44*, 73–82.
- Petersen, S. E., Fox, P. T., Posner, M. I., Mintun, M. A., & Raichle, M. E. (1988). Positron emission tomographic studies of the cortical anatomy of single-word processing. *Nature (London)*, *331*, 585–589.
- Petersen, S. E., Fox, P. T., Snyder, A. Z., & Raichle, M. E. (1990). Activation of extrastriate and frontal cortical areas by visual words and word-like stimuli. *Science*, *249*, 1041–1044.
- Petit, L., Orssaud, C., Tzourio, N., Salamon, G., Mazoyer, B., & Berthoz, A. (1993). PET study of voluntary saccadic eye movements in humans: Basal ganglia-thalamocortical system and cingulate cortex involvement. *Journal of Neurophysiology*, *69*, 1009–1017.
- Rademacher, J., Galaburda, A. M., Kennedy, D. N., Filipek, P. A., & Caviness, V. S., Jr. (1992). Human cerebral cortex: Localization, parcellation, and morphometry with magnetic resonance imaging. *Journal of Cognitive Neuroscience*, *4*, 352–374.
- Reiman, E. M., Fusselman, M. J., Fox, P. T., & Raichle, M. E. (1989a). Neuroanatomical correlates of anticipatory anxiety. *Science*, *243*, 1071–1074.
- Reiman, E. M., Raichle, M. E., Robins, E., Mintun, M. A., Fusselman, M. J., Fox, P. T., Price, J. L., & Hackman, K. A. (1989b). Neuroanatomical correlates of a lactate-induced anxiety attack. *Archives of General Psychiatry*, *46*, 493–500.
- Ross, E. D. (1985). Modulation of affect and nonverbal communication by the right hemisphere. In M. Mesulam (Ed.), *Principles of behavioral neurology*. Philadelphia: F. A. Davis.
- Schiff, H. B., Alexander, M. P., Naeser, M. A., & Galaburda, A. M. (1983). Aphemia: Clinical-anatomic correlations. *Archives of Neurology*, *40*, 720–727.
- Steinmetz, H., & Seitz, R. J. (1991). Functional anatomy of language processing: Neuroimaging and the problem of individual variability. *Neuropsychologia*, *12*, 1149–1161.
- Steinmetz, H., Volkman, J., Jäncke, L., & Freund, H. J. (1991). Anatomical left-right asymmetry of language-related temporal cortex is different in left- and right-handers. *Annals of Neurology*, *29*, 315–319.
- Stroop, J. R. (1935). Studies of interference in serial verbal reactions. *Journal of Experimental Psychology*, *18*, 643–662.

- Talairach, J., & Tournoux, P. (1988). *Co-planar stereotaxic atlas of the human brain*. Stuttgart: Georg Thieme Verlag.
- Wise, R., Chollet, F., Hadar, U., Friston, K. J., Hoffner, E., & Frackowiak, R. S. J. (1991). Distribution of cortical networks involved in word comprehension and word retrieval. *Brain*, *114*, 1803–1817.
- Zattore, R. J., Evans, A. C., Meyer, E., & Gjedde, A. (1992). Lateralization of phonetic and pitch discrimination in speech processing. *Science*, *256*, 846–849.